

CT Appearance of Hypervascular Pancreatic Metastases from Renal Cell Carcinoma before and after Treatment with Sunitinib in One Case

Gambardella D^{1*}, Tedesco M¹, Loria G², Basile M³, Loria S⁴, Gambardella G⁴, Tedesco V⁵ and Loria F²

¹Department of General Surgery (Director M. tedesco) G. Paolo II Hospital, Lamezia Terme, Italy

²Department of Radiology (Director G. Loria), “Giovanni Paolo II” Hospital, Lamezia Terme, Italy

³Department of Medical and Surgical Sciences, University of Messina, Messina, Ital

⁴Department of Medical and Surgical Sciences, University of Catanzaro, Catanzaro, Italy

⁵Department of Medical and Surgical Sciences, University of Plovidiv, Bulgaria

*Corresponding author:

Denise Gambardella,
Department of General Surgery (Director M. tedesco) G. Paolo II Hospital, Lamezia Terme, Italy, Tel: 3385480297;
E-mail: giamby92@hotmail.it;
gambardelladenise@gmail.com

Received: 15 Jun 2022

Accepted: 25 Jul 2022

Published: 30 Jul 2022

J Short Name: COO

Copyright:

©2022 Gambardella D, This is an open access article distributed under the terms of the Creative Commons Attribution License, which permits unrestricted use, distribution, and build upon your work non-commercially.

Citation:

Gambardella D. CT Appearance of Hypervascular Pancreatic Metastases from Renal Cell Carcinoma before and after Treatment with Sunitinib in One Case. Clin Onco. 2022; 6(9): 1-2

1. Clinical Image

The pancreas is an unusual site for tumor metastases, accounting for only 2-5% of all cancers. The renal cell carcinoma as primitive tumour represent the most common pancreatic metastases.

Unlike other forms of non-renal malignancies affecting the pancreas secondarily, which are often associated with widespread systemic disease, renal cell carcinoma may spread to the pancreas as the only secondary site, causing an isolated involvement of the pancreas. Ppancreatic metastatic disease is often discovered during routine surveillance imaging for primary lesions or as an accidental finding on imaging performed for other reasons [1]. With advances in pancreatic surgery a resection , can now be performed safely and is associated with long-term survival in most cases [1, 2]. In fact, surgery is considered the gold standard therapy for the disease. However, the opportunity for surgical exploration is limited. Patients with multiple metastatic sites and widespread systemic disease at the time of diagnosis are not good candidates for resection. These patients usually undergo biological therapy with sunitib (tyrosine kinase inhibitors and molecular targeted therapy, which have been introduced into clinical practice for the treatment of metastatic RCC. 2 Vascular endothelial growth factor (VEGF) inhibitors and the mammalian target of rapamycin (mTOR) radically changed the outcome of patients with metastatic renal cell carcinoma, which was typically a chemoresistant disease [2]. For all these reasons, it is essential to reach an early radiolog-

ical diagnosis of relapse in order to choose whether to perform a metastesectomy or continue with medical therapy [3].

We report the case of a 65-year-old patient affected by RCC who underwent a left nephrectomy. After two years of surgery, during radiological surveillance, on multiphasic Contrast-enhanced Multidetector Computed Tomogrphy (CEMDCT, multiple pancreatic metastases were identified in the head, in the istmo and in the tail of the pancreas. During arterial phase the metastases, sized form few millimeters to 2.6 centimeters , appear as hyperdense lesions compared to normal surrounding parenchyma. A progressive wash-out was foun in the venous and late phase.

The patient, because of extention of the disease, was not suitable for surgical resection of the metastases. For this reason he was treated with sunitinib. After three months of the start of therapy the patient underwent CEMDCT control that showed, a median of two millimeters reduction in sizes of all lesions , also, respect to the last examination was found an inhomogeneous central hypodense areas due to necrosis, in all lesions. Was no found spread to the others organs. The CEMDCT examination revealed no progression of the disease, and a good response of the disease to treatment, and encourage this therapy. At 32 months of follow-up the patient has no other metastatic localizations and the pancreatic ones remained the same, and the patient actually survive with good life quality, without surgery.

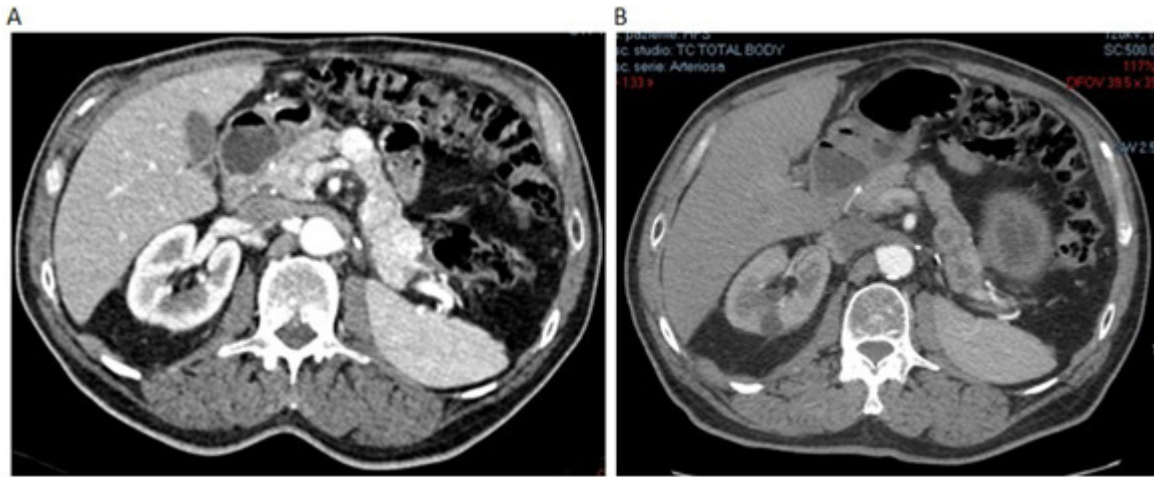


Figure 1: SCANS obtained before (a) and after(b) treatment with sunitinib ;
 a the scans obtained during arterial phase showed homogeneous and complete enhancement of focal pancreatic lesions that appeared well rounded
 b scans obtained during the same phase the lesion clearly appeared hypovascular due to central necrosis because of a positive response to the treatment

References

1. Cheng SKH, Chuah KL. Metastatic Renal Cell Carcinoma to the Pancreas: A Review. *Arch Pathol Lab Med.* 2016; 140(6): 598-602.
2. Yuasa T, Inoshita N, Saiura A, Yamamoto S, Urakami S, Masuda H, et al. Clinical outcome of patients with pancreatic metastases from renal cell cancer. *BMC Cancer.* 2015; 15: 46.
3. Vincenzi M, Pasquotti G, Polverosi R, Pasquali C, Pommeri F. Imaging of pancreatic metastases from renal cell carcinoma. *Cancer Imaging.* 2014; 14(1): 5.