

Uretero-Enteric Anastomosis Stricture after Urinary Diversion; Detailed Analysis of The Responsible Factors and Their Impact on The Management

Moeen AM^{1*}, Shahat A¹, Soliman A², Hameed DA¹ and Reda A¹

¹Department of Urology, Assiut University Hospital, Assiut, Egypt

²Department of General Surgery, Assiut University Hospital, Assiut, Egypt

*Corresponding author:

Ahmed M. Moeen,
Department of Urology, Assiut University Hospital, Assiut, Egypt, Tel: (+2) 01003960931; E-mail: moeen3@yahoo.com; ahmedmoeen@aun.edu.eg

Received: 19 Apr 2022

Accepted: 28 Apr 2022

Published: 04 May 2022

J Short Name: COO

Copyright:

©2022 Moeen AM. This is an open access article distributed under the terms of the Creative Commons Attribution License, which permits unrestricted use, distribution, and build upon your work non-commercially.

Citation:

Moeen AM, Uretero-Enteric Anastomosis Stricture after Urinary Diversion; Detailed Analysis of the Responsible Factors and their Impact on the Management Uretero-Enteric Anastomosis Stricture after Urinary Diversion; Detailed Analysis of the Responsible Factors and their Impact on the Management. Clin Onco. 2022; 6(5): 1-7

Keywords:

Uretero-enteric; Anastomosis; Conduit; Cystectomy; neobladder; stricture

Abbreviations:

RCX: Radical cystectomy; UD: Urinary diversion; UEA: Uretero-enteric anastomosis; UEAS: Uretero-enteric anastomosis stricture; UUT: Upper urinary tract; PCN: Percutaneous nephrostomy; GIT: Gastrointestinal tract; RTH: Radiotherapy; UTI: Urinary tract infection; BMI: Body mass index; ASA: American Society of Anesthesiology; Yrs: Years; RARCS: Robotic Assisted Radical Cystectomy

1. Abstract

1.1. Objective: To report the lessons we have learned in the management of uretero-enteric anastomosis stricture (UEAS) in a tertiary urology center over a decade of experience.

1.2. Methods: This study included 52 patients (69 renal units) with UEAS (36 males and 16 females). Endoscopic treatment was utilized for short, passable and early strictures, while open surgical revision for impassable and failed endoscopic treatment. Complications of treatment were graded according to the modified Clavien system. Patients were followed up regularly for one year to assess the outcomes of treatment.

1.3. Results: Age range of the patients was 48-71 years. Median (Interquartile range [IQR]) of follow up was 20 (18-28) months. Hospital stay ranged from 2-3 days in patients subjected for endoscopic treatment and 3-15 days in case of open surgery. In patients who underwent open surgical revision, 2 (5.4%) patient had minor vascular injury (external iliac artery and vein, each in one patient) and 2 (5.4%) patients had enteric injuries which were primarily repaired. After treatment, abdominal US showed decompression of the pelvicalyceal system in 41 patients and mild residual pelvi-

calyceal dilation in 11. Recurrent strictures developed in 7 (13.5%) patients (4 after open treatment and 3 after endoscopic treatments) on follow up

1.4. Conclusions: Endoscopic treatment of UEAS is an appealing first choice that utilizes regional anesthesia, has minimal or no blood loss, results in minimal postoperative complications and shorter hospitalization. However, open surgical treatment is considered the suitable choice for long impassable strictures.

2. Introduction

Radical Cystectomy (RCX) and Urinary Diversion (UD) is the standard treatment for muscle invasive bladder cancer. It is a multistep surgery with high rate of complications even in highly experienced centers. One of its crucial steps is the Uretero-Enteric Anastomosis (UEA) [1].

Uretero-enteric anastomosis stricture (UEAS) management is the most frequent secondary surgical procedure after UD [2]. Its rate varies from 1.3–13%. Its occurrence may be related to the preoperative state of ureters, how it were dissected and anastomosed to the future reservoir and the presence of prolonged leakage postoperatively [3].

UEAS management is a challenging task due to the following reasons; the endoscopic identification of the site of UEA between the intestinal rugae may be so difficult. Moreover, in open surgical treatment, abdominal re-exploration should be done with great caution due to adherence of the intestine to the old abdominal suture line, the surgical field itself is full of adhesion after RCX, the ureters may be adherent to the pelvic great vessels and the left ureter may be tunneled under the sigmoid colon. Furthermore, it is crucial to preserve a vascular ureter with a sufficient length for the redo reimplantation.

Herein, we analyze the factors affecting the management of UEAS and reporting our experience in 52 patients [69 renal units].

3. Patients and Methods

Out of 523 patients who underwent RCX and UD between 2008 and 2019, 76 (14.5%) patients with UEAS were identified. Twenty-four (4.6%) patients were excluded due to malignant obstruction or oncological failure. Fifty-two (9.9 %) patients (37 males and 15 females) with benign strictures (35 unilateral and 17 bilateral) were enrolled in the study. The utilized techniques of UD were the modified Studer's [4], Hautmann's [1] neobladders and ileal conduit [5]. Inclusion criteria were patients with benign UEAS, absence of oncological failure, and ipsilateral good renal function.

Exclusion criteria were UEAS due to lymph node compression, malignant obstruction and positive urine cytology.

The preoperative pathology, the presenting symptoms, history of radiotherapy or chemotherapy and history of previous endoscopic treatment were recorded. Full lab investigations were done including urine analysis \pm urine culture, urine cytology and routine laboratory work up. Radiological investigations included abdominal US and enhanced pelvi-abdominal CT scan in all patients to exclude oncological failure or malignant obstruction. In patients with a neobladder and dilated Upper Urinary Tract (UUT) with significant Post-Voiding Residual Urine (PVR), voiding pouchography was performed to exclude reflux. In patients with a Percutaneous Nephrostomy (PCN) for former drainage of infection or improving the renal function, descending nephrostogram was done to determine the level of obstruction.

The strategy of management was as follows: patients with short, passable, unilateral and early strictures were subjected to endoscopic treatment first. On the other hand, long, impassable, late strictures, bilateral pathology and previous history of radiotherapy or failed endoscopic treatment were subjected to open surgery (figure 1).

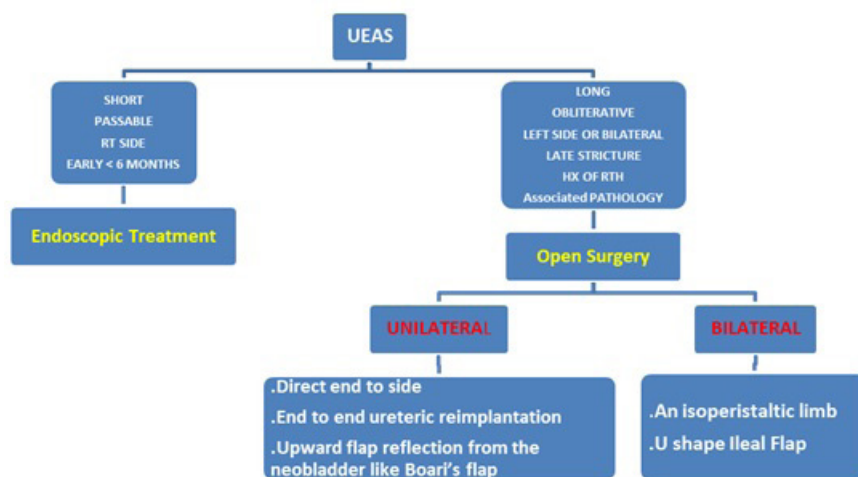


Figure 1: An algorithm for management of UEAS

In patients indicated for endoscopic treatment, retrograde URS was tried firstly. In case of difficult identification of the site of UEA during retrograde URS, antegrade percutaneous assisted identification of the UEA site by fluoroscopy was performed. In open surgery, certain precautions were adopted during abdominal re-exploration to avoid inadvertent injury to the surrounding structures; all operations were performed by high volume surgeons, abdominal incision was started 5 cm cephalic to the previous incision to begin in fresh field, the overlying intestinal adhesion were carefully dissected, pedicle preservation of the neobladder or the conduit then follows, the site of UEA was identified and marked

by vessel loop, and the ureter was dissected carefully to preserve its adventia maintaining healthy and lengthy ureter. Common to all patients, JJ stents was fixed for 2 months.

Follow up visits were scheduled at one month postoperatively and every three months thereafter by serial abdominal US. Success of treatment was defined by symptomatic improvement, improvement of renal function if it was preoperatively elevated, resolution of hydronephrosis and no need for ancillary procedure.

The Kolmogorov-Smirnov test was used to test the normality of variables. The Mann-Whitney U-test was used for non-normal-

ly distributed variables. Categorical data differences were tested with Chi-square test or Fisher's exact test as appropriate. All tests were two-sided and statistical significance was considered at $p < 0.05$. Data are presented as mean (standard deviation), median (interquartile range [IQR]) or numbers (percentages) as appropriate. Statistical analyses were performed using SPSS statistics version 23.0 (IBM Corp., Armonk, NY, USA).

4. Results

The age range of the patients was 48-71 years. Median (Interquartile range [IQR]) of follow up was 20 (18-28) months. Hospital stay ranged from 2-3 days in patients treated endoscopically and 3-15 days after open surgery. Interventions were done under spinal anesthesia for endoscopic treatment and a combination of spinal and general anesthesia in patients underwent open surgery. Table-1 shows patients' and stricture characteristics.

Twenty-nine (55.8%) patients developed early stricture [within 6 months] after RCX and 23 (44.2%) developed late stricture [> 6 months]. The median time to develop stricture (interquartile range) was 16 (2–23) months. UEAS was unilateral in 35 (67.3%) patients and bilateral in 17 (32.7%). Patients with unilateral obstruction presented with renal pain, which was dull aching and progressive, with fever in 20 (38.4%) patients. Patient with bilateral renal obstruction presented with bilateral renal pain in 8 patients, high-grade fever in 4 and elevated serum creatinine in 5 for which bilateral PCN tubes were placed. This was followed by resolution of fever and normalization of renal function.

Enhanced abdominal CT scan revealed grade II hydronephrosis in 60 renal unites and grade III in 9 renal unites. The length of the stricture segment was < 1 cm in 25 (48%) patients and > 1 cm in 44 (52%). The type of the primary ureteric reimplantation in those patients was a refluxing end to side or end to end fashion to the conduit or to the isoperistaltic limb of the modified studer or Hautmann neobladder (Table 2). No intraoperative complications were encountered in patients who underwent endoscopic treatment. In

patients who underwent open surgical revision, 2 (5.4%) patient had minor external iliac artery and vein, each occurred in one patient, which were repaired by 6/0 vicryl. Another 2 (5.4%) patients had enteric injuries which were primarily repaired.

During endoscopic treatment, identification of the site of the UEA was easy in 6 patients [6 renal units] with primary end to end ureteric reimplantation. On the contrary, in 9 (60%) patients [14 renal units] percutaneous assisted URS identification of the UEA was required. Balloon dilation [UroMax Ultra™, 21 Fr \times 4 cm] of the stricture site was performed in 7 (46.7%) patients and laser endo-ureterotomy in 8 (53.3%). Absence of any UUT neoplastic growth was confirmed before JJ stent fixation. The latter was removed after 2 months.

Multiple types of redo open ureteric reimplantation were applied. Direct end to side [16 patients] or end to end [11 patients] ureteric reimplantation to the conduit or the isoperistaltic limb was performed. Upward flap reflection from the neobladder like Boari's flap was configured in 3 patients. Isolation of 20 cm of the ileum was required in 7 patients. The latter was configured either as an isoperistaltic limb in 4 patients or in a U shape to treat bilateral stricture in 3 patients. The base of the U was anastomosed to the pouch and the ends of the U were used as a double chimney to which the ureters were anastomosed (Table 2, figure 2).

The primary suturing was interrupted in 14 patients and continuous in 38. However, interrupted suturing was done in all patients during management of UEAS. Common to all techniques, a JJ stent was fixed for 2 months in case of neobladders and 7 Fr ureteric stents for 2 weeks in case of conduits. Operative time was significantly longer in open surgical revision ($p 0.001$). After the ureteric stents removal, abdominal US showed decompression of the pelvicalyceal system in all patients. Recurrent strictures developed in 7 (13.5%) patients (3 after endoscopic balloon dilation and 4 after open revisions) during the 1st year postoperatively. Table-2 summarizes the results and the postoperative complications.

Table 1: Patients' characteristics

Variable	Open surgery [Group I]	Endoscopic treatment [Group II]	P value
Number of patients (%)	37 (71.1%)	15 (28.9%)	
Age (M \pmSD)	59.8 \pm 4.62	60.67 \pm 4.75	0.592
Sex			
Males	26 (70.3)	11 (73.3%)	0.825
Females	11 (29.7)	4 (26.7%)	
BMI (mean \pmSD)	22.92 \pm 1.19	23.06 \pm 1.2	0.624
Smoking History			
Yes	20 (54.1%)	9 (60%)	0.696
No	17 (45.9%)	6 (40%)	
Preoperative co-morbidity grade			
None	16 (43.2%)	8 (53.4%)	0.074
Mild	13 (35.1%)	2 (13.3%)	
Moderate	8 (21.6%)	3 (20%)	
Sever	-	2 (13.3%)	
Preoperative pathology			
TCC	20 (54.1%)	11 (73.3%)	0.47

SCC	10 (27%)	3 (20%)	
Adenocarcinoma	4 (10.8%)	-	
Micropapillary carcinoma	3 (8.1%)	1 (6.7%)	
Preoperative pathological tumor stage			
Organ confined pT2, pN0	29 (78.4%)	8 (53.3%)	0.187
Non organ confined: pT3-pT4a, pN0	4 (10.8%)	4 (26.7%)	
Lymph node-positive: p N+	4 (10.8%)	3 (20%)	
Co-morbid conditions			
Diabetes mellitus	13 (35.1%)	3 (20%)	0.595
Hypertension	9 (24.3%)	4 (26.7%)	
Cardio-pulmonary disease	4 (10.8%)	1 (6.7%)	
None	11 (29.7%)	7 (46.7%)	
Neoadjuvant chemotherapy	19 (51.4%)	5 (33.3%)	
Preoperative RTH	8 (21.6%)	3 (20%)	0.364
Type of diversion			
Modified Studer OBS	12 (32.5%)	6 (40%)	0.873
Hautmann OBS	14 (37.8%)	5 (33.3%)	
Ileal conduit	11 (29.7%)	4 (26.7%)	

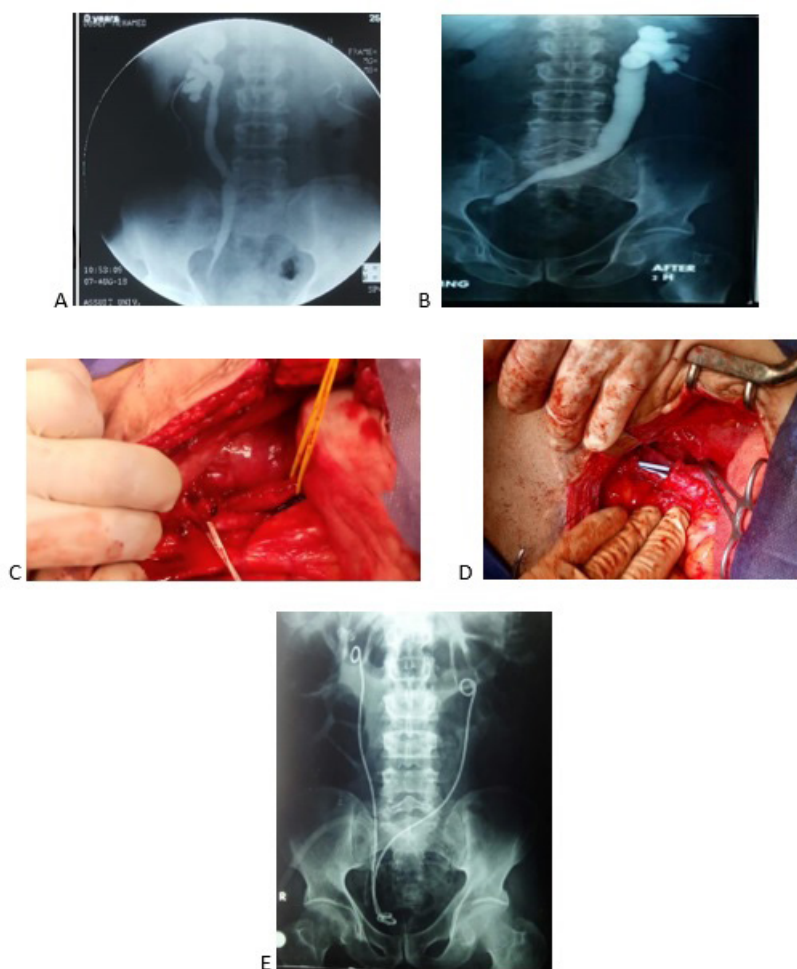


Figure 2: Bilateral UEAS in male patient with Hautmann ileal neobladder treated with upward flap reconstruction

A-RT Descending nephrostogram showing complete arrest of the dye

B- LT Descending nephrostogram showing complete arrest of the dye

C- Bilateral ureteric identification and stricture delineation

D- Upward flap reconfiguration from the pouch and anastomosis to both ureters

F- KUB showing bilateral JJ stents

Table 2: Uretero-enteric stricture characteristics and postoperative complications

	Open surgery	Endoscopic treatment	P value
Laterality			
Unilateral	25 (67.6%)	10 (66.7%)	0.95
Bilateral	12 (32.4%)	5 (33.3%)	
Preoperative type of ureteral reimplantation			
Refluxing end to side	25 (67.6%)	9 (60%)	0.603
Refluxing end to end	12 (32.4%)	6 (40%)	
Types of sutures			
Interrupted	8 (21.6%)	6 (40%)	0.176
Running	29 (78.4%)	9 (60%)	
History of prolonged urinary leakage			
YES	8 (21.6%)	4 (26.7%)	0.696
NO	29 (78.4%)	11(73.3%)	
History of PCN placement			
YES	11 (29.7%)	5 (33.3%)	0.799
NO	26 (70.3%)	10 (66.7%)	
Time to stricture occurrence			
Early (< 6 mo)	20 (54.1%)	9 (60%)	0.696
Late (> 6 mo)	17 (45.9%)	6 (40%)	
Operative time (min)	186.86 ± 9.86	66.33 ± 6.91	0.001
Types of treatment			
Direct end to side	16 (43.2%)	-	-
Direct end to end	11(29.7%)	-	
Upward ileal flap	3 (8.1%)	-	
Isoperistaltic limb	4 (10.8%)	-	
U shaped ileal segment	3 (8.1%)	-	
Balloon dilation	-	7 (46.7%)	
Laser incision	-	8 (53.3%)	
Recurrence of stricture			
Yes	4 (10.8%)	3 (20%)	0.379
No	33 (89.2%)	12 (80%)	
Postoperative modified Clavien complications:			
Blood transfusion	10 (27%)	-	0.28
Postoperative fever	6 (16.2%)	5 (33.3%)	
Ileus	4 (10.8%)	2 (13.3%)	
Sepsis	5 (13.5%)	3 (20%)	
Wound infection	2 (5.4%)	-	
wound dehiscence	2 (5.4%)	-	
DVT	1 (2.7%)	-	
Intestinal leak	1 (2.7%)	-	
None	6 (16.2%)	5 (33.3%)	

5. Discussion

UEAS after UD could be managed by open, endoscopic, laparoscopic and robotic approaches. However, the two commonly used approaches are open and endoscopic techniques. Minimally invasive endoscopic management could be the preferred first option, whenever possible, to avoid the complications of open surgery [6]. Generally, good UEA should be water tight, tension free, mucosa to mucosa, spatulated, stented and using fine sutures. Sometimes, the left ureter may pass to the right side under the sigmoid colon. So, it should have a smooth curve without angulation or twisting. Handling should be a-traumatic [7]. Commonly, UEAS rate is higher in the anti-refluxing techniques [8]. Hautmann stated that; if the reservoir is large volume and low pressure; the refluxing anastomosis is the technique of choice; as it does not affect the renal function, technically easier and poses less risk of stricture. Furthermore, multiple randomized trials show that the use of anti-refluxing UEA is not necessary [9, 10]. We prefer to do UEA as

the last step during the reconstruction to avoid any traction during the conduit-stoma or urethro-enteric anastomosis.

Stricture occurrence may be due to benign or malignant causes. Benign Strictures may be due to poor ureteral condition as in Tuberculosis or Bilharziasis, post radiotherapy, poor surgical technique as angulation or twisting, postoperative urinary tract infection (UTI), prolonged leakage and stent slippage or its early removal [9]. Regarding the robotic surgical technique, there was no difference in the rate of UEAS between it and open surgery [11]. Ahmed et al. showed that a higher BMI, intra-corporeal UD, longer length of the resected right ureter, postoperative UTI and leakage were significantly associated with UEAS following RARC [2]. Malignant obstruction whether intrinsic or extrinsic compression should be excluded in every case either by imaging or endoscopic surveillance.

In a study evaluating the factors affecting the development of UEAS that included 2888 patients, UEAS developed in 123 pa-

tients. On multivariate analysis, the significant factors were; higher BMI ($p=0.002$), ASA score >2 ($p<0.0001$), lymph node positive disease ($p=0.027$), 30-day postoperative complications grade 3+ ($p=0.017$), male gender and history of prior abdominal surgery ($p=0.0001$). The risk of stricture/10 yrs was 1.9 % without history of previous abdominal surgery versus 9.3% with their counterparts [2].

In a study evaluating the effect of diabetes and elevated serum urea level, 14/133 patients (10.5%) developed strictures. Diabetes and elevated serum urea level (>7.1 mmol/L) increased the risk for UEAS development (odds ratio 4.31 and 4.28, respectively; $p<0.05$ for each). This was explained as diabetes is a micro-vascular disease; the distal ureter becomes sensitive to the reduced perfusion and became, especially after dissection, unable to compensate for its relative ischemia. This may predispose to UEAS and impairs tissue-healing [12]. In our study, the number of diabetic patients were 13 (35.1%) in group I and 3 (20%) in group II. Regarding the laterality, UEAS tends to affect the left side more than the right. This may be due to the increased mobilization and tunneling under the sigmoid colon to reach the other side [13]. But, the increased left sided UEAS rate is inherent to all orthotopic reservoirs except the (W) shape which may not require this tunneling [14]. In our study, the left sided strictures were present in 38/52 patients (29 in group I and 9 in group II). In those patients, the left ureter was tunneled under the sigmoid through a large hole in the mesentery below the level of inferior mesenteric artery.

Hautmann stated that, the preoperative state of the ureter greatly affects the postoperative outcome of UEA. Preoperative Hydronephrosis increased the stricture rate ($p= 0.012$). This may be due to increased collagen deposition in the wall of the ureter [14]. In our study, preoperative hydronephrosis was present in 16/52 patients (11 in group I and 5 in group II).

Regarding the suturing technique, whether continuous or interrupted, and its impact on the UEA, it was shown that the stricture rate per ureter was 8.5% (25/293) and 12.7% (27/213) in the interrupted and running groups, respectively ($p 0.14$). On multivariate analysis, the running technique was associated with UEAS ($p 0.05$). Kaplan-Meier analysis showed a trend toward higher freedom from stricture for the interrupted anastomosis ($p 0.06$) [15]. In our study, the primary suturing was interrupted in 14 patients and continuous in 38. However, interrupted suturing was done in all patients during management of UEAS.

Multiple factors affect UEAS management such as the ipsilateral renal function, laterality, stricture length, time to occurrence, etiology, type of anastomosis, and the surgeon experience. So, full details of the diversion process must be reported for any future surgical intervention. During management, each re-implantation technique has its peculiar characters. For example, end-side UEA to an isoperistaltic limb is difficult in retrograde endoscopy. It may need an antegrade assisted fluoroscopic approach. However, in clinicsofoncology.com

open surgery, the anterior location of the isoperistaltic limb facilitates identification of the ureter with no need to open the reservoir [16]. If the serous-lined extramural tunnel was used, it is ideal for retrograde endoscopy, but in open surgery, the reservoir \pm the tunnel will be opened [17]. In the ileal conduit, the Wallace anastomosis helps to access the UEA in case of endoscopic treatment than the end to side UEA.

Endoscopic treatment of UEAS may be performed in an antegrade or retrograde approaches. It is often the first choice especially in patients with strictures ≤ 1 cm [13, 18]. It avoids a lot of the hazards that may occur with laparoscopic or open surgery owing to marked intra-abdominal adhesions and allows the patient's return to normal daily activity sooner [7-19].

Modalities of endoscopic treatment include balloon dilation, endoscopic incision using cold knife or laser with success rate up to 70%. Factors like stricture length >1 cm, stricture presenting <6 months after surgery and left sided stricture are associated with poor outcomes [20]. For left sided strictures, endoscopic incision should be done cautiously to avoid injury to the sigmoid mesentery which is very close. This, taken with the lower success rates of endoscopic approaches on this side, supports the priority of open repair of left sided strictures [4, 21].

In our study, endoscopic dilation was performed in 15 patients [balloon dilation in 7 (46.7%) and laser incision in 8 (53.3%)]. The success rate was 80 %. Three patients (20%) developed recurrence of stricture after balloon dilation. A study evaluating the endoscopic balloon dilation of UEAS [17 patients] compared to a control group [21 patients] who underwent open surgery, found that the success rate was similar [82.6% and 85.7% respectively]. However, a significantly reduced mean operative time, intraoperative blood loss and postoperative hospital stay were found in the first group [22]. This is in accordance with our results.

Open surgery is considered the treatment of choice for UEAS with a success rate up to 90%. However, it is associated with a high incidence of blood loss, intraoperative complications and high re-operation rates [23]. The indication of open surgery as a primary intervention is radiologically complete obstruction of the stricture or stricture length greater than 1 cm. Also, it is considered the second step after unsuccessful endoscopic intervention [24]. However, open surgical treatment is challenging for the following reasons; the UEA is a deep posterior anastomosis with dense overlying intestinal adhesion, pedicle preservation of the neobladder or the conduit is critical, the left ureter passes under the sigmoid colon and should be dissected carefully preserving healthy and lengthy ureters with avoidance of inadvertent injury to surrounding structures.

To overcome the excessive dissection in open surgery, some authors described the uretero-ileal bypass technique. In this technique, a healthy part of the ureter was opened and anastomosed to the nearby neobladder. Small number of patients and limited

follow up were limitation of this technique [25]. Few studies reported the initial experience of labaroscopic/robotic management of UEAS is present. A small number of patients and high level of experience are required [2-26].

The limitations of our study include; the small number of patients and its retrospective nature.

6. Conclusion

UEAS is not uncommon time-dependent complication after UD. The endoscopic management is an appealing first choice as it utilizes regional anesthesia, has minimal or no blood loss, results in minimal postoperative complications and shorter hospitalization. However, open surgical treatment guarantees good results for bilateral, complex strictures in presence of high volume surgeons.

References

- Hautmann RE, De Petriconi RC, Volkmer BG. Lessons Learned From 1,000 Neobladders: The 90-Day Complication Rate. *J Urol*. 2010; 184: 990-4.
- Youssef E. Ahmed, Ahmed A. Hussein, Paul R. May, Et Al. Natural History, Predictors And Management Of Ureteroenteric Strictures After Robot Assisted Radical Cystectomy. *J Urol*. 2017; 198: 567-74.
- Elicer Kurzer, Raymond J Leveillee. Endoscopic Management Of Ureterointestinal Strictures After Radical Cystectomy. *J Endourol*. 2005;19 (6):677-82.
- Moeen AM, Hameed DA, Gadelkareem RA, Abdelsalam YM, Abdel-Hafez SES, Ahmed AI. Functional Evaluation Of A Modified Studer Ilealneobladder. *African Journal of Urology*. 2016; 22(3): 153-161
- Colombo R, Naspro R. Ileal Conduit as The Standard For Urinary Diversion After Radical Cystectomy For Bladder Cancer. *European Urology Supplements*. 2010; 9: 736-44.
- Moeen AM, Safwat AS, Elderwy AA, Behnsawy HM, Osman MM, Hameed DA. Management of Neobladder Complications: Endoscopy Comes First. *Scandinavian Journal of Urology*. 2017; 51(2): 146-51.
- Mattei A, Birkhaeuser FD, Baermann C, Warncke SH, Studer UE. To Stent Or Not To Stent Perioperatively The Ureteroileal Anastomosis Of Ileal Orthotopic Bladder Substitutes And Ileal Conduits? Results Of A Prospective Randomized Trial. *J Urol*. 2008;179: 582-6.
- Hautmann RE, Volkmer BG, Schumacher MC, Gschwend JE, Studer UE. Long-Term Results Of Standard Procedures In Urology: The Ileal Neobladder. *World J Urol* 2006; 24:305–14.
- Skinner EC, Fairey AS, Groshen S, et al. Randomized Trial of Studer Pouch Versus T-Pouch Orthotopic Ileal Neobladder In Patients With Bladder Cancer. *J Urol*. 2015: 194: 433-40.
- Shaaban AA, Abdel-Latif M, Mosbah A, et al. A Randomized Study Comparing An Antireflux System With A Direct Ureteric Anastomosis In Patients With Orthotopic Ileal Neobladders. *BJU International*. 2006; 97(5): 1057-62]
- Anderson CB, Morgan TM, Kappa S, et al. Ureteroenteric Anastomotic Strictures After Radical Cystectomy-Does Operative Approach Matter? *The Journal Of Urology*. 2017; 189: 541-7]
- Nathan Hoag, MD, Nathan Papa, MD; Bhawanie Koonj Baharry. Diabetes And Elevated Urea Level Predict For Uretero-Ileal Stricture After Radical Cystectomy And Ileal Conduit Formation. *Can Urol Assoc J* 2017; 11(3-4): E88-92
- Schondorf D, Meierhans-Ruf S, Kiss B, et al. Ureteroileal Strictures After Urinary Diversion With An Ileal Segment – Is There A Place For Endourological Treatment At All? *J Urol* 2013; 190: 585-90.
- Hautmann RE, De Petriconi R, Kahlmeyer A, et al. Preoperatively Dilated Ureters Are A Specific Risk Factor For The Development Of Ureteroenteric Strictures After Open Radical Cystectomy And Ileal Neobladder. *J UROL*. 2017; 198(5): 1098-1106.
- Michael C. Large, Joshua A. Cohn, Kyle J. Kiriluk. The Impact Of Running Versus Interrupted Anastomosis On Ureterointestinal Stricture Rate After Radical Cystectomy. *J Urol*. 2013; 190: 923-7.
- Hollowell CM, Christiano AP, Steinberg GD. Technique Of Hautmann Ileal Neobladder With Chimney Modification: Interim Results In 50 Patients. *J UROL*. 2000; 163(1): 47-51]
- Abol-Enein H, Ghoneim MA. Functional Results Of Orthotopic Ileal Neobladder With Serous-Lined Extramural Ureteral Reimplantation: Experience With 450 Patients. *J Urol*. 2001; 165: 1427–32.
- Emiliani E, Breda A. Laser Endoureterotomy And Endopyelotomy: An Update. *World J Urol*. 2015; 33, 583–587.
- Razvi HA, Martin TV, Sosa RE, et al. Endourological Management Of Complications Of Urinary Intestinal Diversion. *AUA Update Ser*. 1996; 15: 174–9.
- Nassar OA, Alsafa ME. Experience With Ureteroenteric Strictures After Radical Cystectomy And Diversion: Open Surgical Revision. *Urology*. 2011; 78(2): 459-65]
- Karmolowsky EV, Clayman RV, Weyman PJ. Endourological Management Of Ureteroileal Anastomotic Stricture: Is It Effective? *J Urol*. 1987; 137: 390.
- Yu HL, Ye LY, Lin MH, et al. Placement Of Dual Double-J Stents Following High-Pressure Balloon Angioplasty For Treatment Of Ureter-Ileum Bladder Anastomosis Stricture. *Journal Of Southern Medical University*. 2011; 31(7): 1279-81.
- Laven BA, O'connor RC, Gerber GS, et al. Long-Term Results Of Endoureterotomy And Open Surgical Revision For The Management Of Ureteroenteric Strictures After Urinary Diversion. *J Urol*. 2003; 170(4): 1226-30]
- Wishahi M, Elganzoury H, Elkhouly A. Detour Technique, Dipping Technique, Or Ileal Bladder Flap Technique For Surgical Correction Of Uretero-Ileal Anastomotic Stricture In Orthotopic Ileal Neobladder. *Int Braz J Urol*. 2015; 41: 796-803.
- Padovani GP, Mello MF, Coelho RF. Ureteroileal Bypass: A New Technic To Treat Ureteroenteric Strictures In Urinary Diversion. *Int Braz J Urol*. 2018; 44(3): 624-628
- Anderson CB, Morgan TM, Kappa S, et al. Ureteroenteric Anastomotic Strictures After Radical Cystectomy-Does Operative Approach Matter? *The Journal Of Urology*. 2017; 189: 541-7]